



## CASE SERIES

### A Conservative Approach for Restoration of Grossly Decayed Vital Posterior Teeth using Fiber Reinforced Composites-A Case Series

Barkha J<sup>1</sup>, Sathyanarayanan R<sup>2</sup>

**ABSTRACT:** Fibers are becoming very popular for reinforcement of polymer-based dental materials in all the other fields of dentistry other than restorative dentistry. Placement of fibers in restorative dentistry has not been discussed in detail, in the literature, before. This article presents management of six grossly damaged carious disfigurements with vital pulp and sound periodontal health. After considering the resistance, retention and biological form of the tooth and patients' esthetic demands; fiber reinforced composite restoration was decided as the best treatment option for these cases. It has been suggested as a very conservative concept to use fiber reinforced restoration in restoring extensively damaged teeth. The guidelines for the different placement of fibers have been explained with six cases having varying degree of destruction. Hence, this case series can provide ease for the readers to decide the size, direction, number and other factors while restoring a complex case with fiber reinforced resin restoration.

**Keywords:** *Complex restoration, polyethylene fiber, woven fiber, fiber reinforced composite, ribbon fibres*

A restorative dentist is confronted with restoration of extensively damaged vital teeth in routine. The structural damage in a vital tooth can present in one of the following forms:

- Loss of cusps is more than 1/3 to 1/2 of intercusp distance
- More than two surfaces are involved
- All cusps are involved
- Axial angles are involved
- Two marginal ridges and crossing ridges are involved.<sup>1,2,3</sup>

Complex restorative procedures with extra

resistance and retention forms are advocated for management of such cases. Complex restorations are either direct restorations such as silver amalgam or indirect restorations like cast metal restoration, indirect resin composite, ceramic restoration. These restorations can be planned depending upon the case, requirement of strength, tooth

Scan the QR code with any smart phone scanner or PC scanner software to download/ share this publication



conservation, esthetics, reinforcement, longevity, cost and biocompatibility.<sup>3</sup>

The continuous developments of total etch adhesive systems and the improvement of physical and mechanical properties of resin bonded composite have revolutionized the restorative dentistry. Previous literature has thoroughly investigated the filler phases, resin compositions, and curing conditions to improve the mechanical properties of filler composites.<sup>4,5,6</sup> Fibers are increasing being used dentistry other than restorative dentistry.<sup>6,7,8</sup> Placement of fibers in restorative dentistry has not been discussed in detail in the literature before.

Incorporation of fibres can increase strength, stiffness, fracture resistance and toughness of resin composites. Concerns related to creep and shrinkage is minimized due to relative decrease in volume of resin matrix. Fiber reinforcement depends on the orientation, type and geometric configuration of fibers in the composite. There are different types of fibers which can reinforce composite restoration e.g. glass, carbon, polyethylene etc. A brief classification of fiber reinforcement has been mentioned below.<sup>7,8</sup>

### **Classification of Fibers used for Reinforcement:**

#### **According to types of Fibers**

Polyethylene fibers

Glass fibers

Carbon Fibers

Kevlar

#### **According to Fiber Orientation**

Unidirectional

Braided

Woven

#### **Resin-Impregnated or Non-Impregnated**

Non resin impregnated - polyethylene weaves, glass weaves

Resins (hand formed) - unidirectional glass materials, woven glass forms<sup>7,8,9,10</sup>

Ribbon is a commercially available polyethylene fiber with patented leno weave pattern and lock stitch design.<sup>7,8</sup> The versatility of ribbon use is because of its superior properties like high strength, leno weave structure, esthetics, biocompatibility. It has applications in periodontal splinting, endodontic post and cores, trauma stabilization, orthodontic retainers, maintaining diastema closure, some other repairs and problem solving issues. Here in this article, there is a brief description of few complex cases done with fiber (ribbon) reinforced composite in Department of Conservative Dentistry, Bapuji Dental College, Davangere, India.

#### **CASE REPORT- 1 (Fig 1)**

##### Chief complaint, clinical examination and diagnosis:

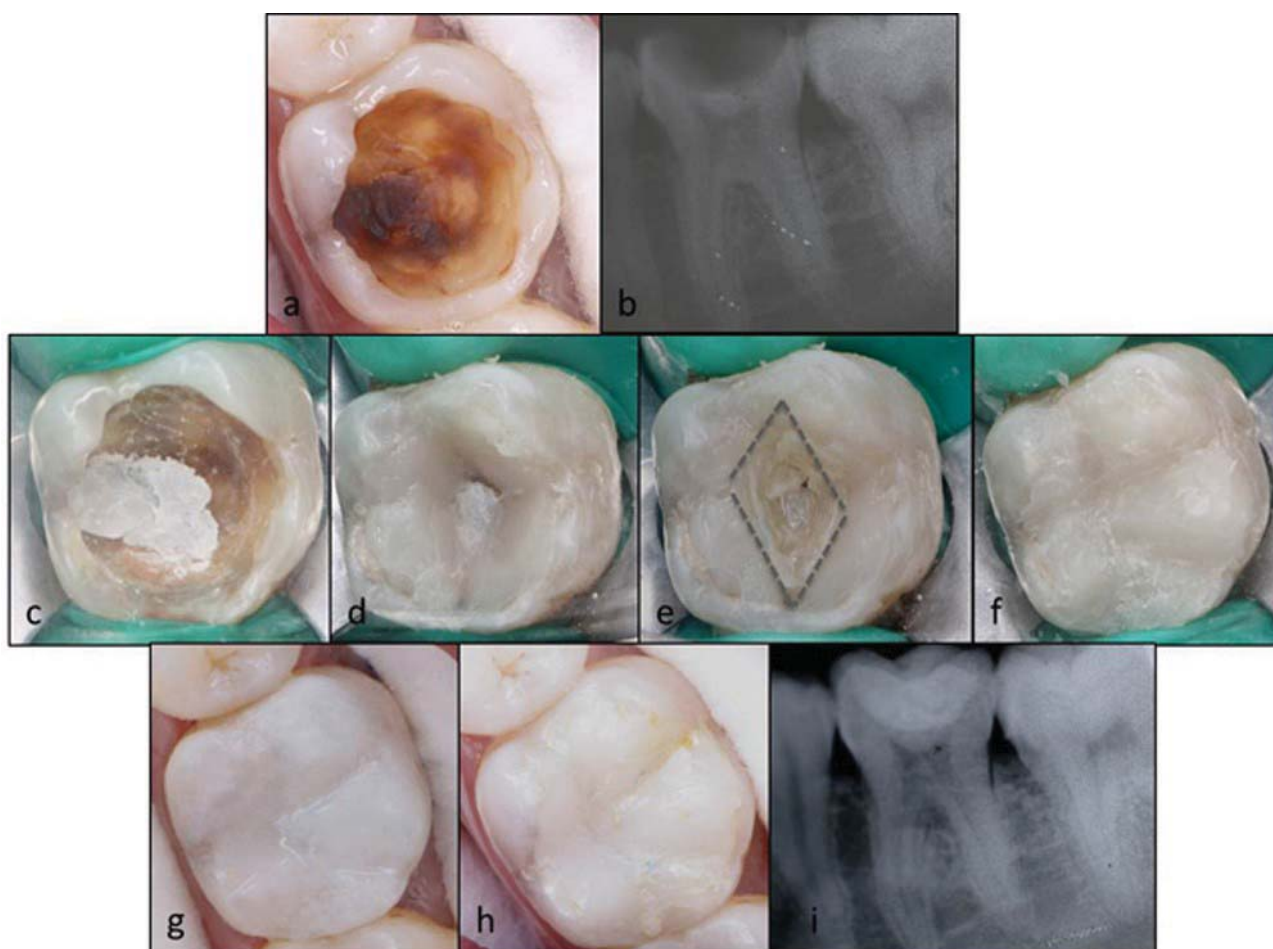
A 28 years old male patient reported with a chief complaint of decay and food lodgment in his left lower back tooth. He did not have

any pain in the same tooth but slight discomfort was there. On visual examination, there was Class I caries on mandibular left molar with carious involvement of mesiobuccal, mesiolingual, distobuccal, distolingual cusps except marginal ridges.(Fig 1a) Probing test gave negative result. The periapical radiograph showed occlusal radiolucency in dentin with no periapical

changes (Fig 1b). The case was diagnosed as occlusal cavitated carious disfigurement with deep dentin involvement.

#### Treatment Procedure:

All the soft caries was excavated and GIC base was applied (Fig 1c). The first increment of composite (Filtek Z350, 3M ESPE; India) was placed on the pulpal floor to create the



**Fig– 1: Case report 1**

- a.** Preoperative occlusal view of left mandibular first molar
- b.** Preoperative radiograph of left mandibular first molar
- c.** Pulp protection with glass ionomer cement
- d.** Inclined cuspal planes created for lost cusps
- e.** Bonding of four pieces of Ribbond over the inclines
- f.** Restoring cuspal anatomy with composite restoration
- g.** Immediate post operative occlusal view after finishing and polishing
- h.** 9 months follow up
- i.** Post operative follow up radiograph

inclined cuspal plane of all lost cusps. (Fig 1d) The thickness of the increment was variable so that at least 1.5mm of space was present from occlusal surface for the final increment. Over the created incline planes, four pieces of ribbon (Ribbon bondable reinforcement ribbon, US) of 2mm width of variable length, impregnated with bonding agent (Adper Single Bond, 3M ESPE; India), were placed on all the four cusps (mesiobuccal, distobuccal, mesiolingual and distolingual) (Fig 1e). The final increment of composite was done over ribbon (Fig 1f) Finishing and polishing of the restoration was done after checking for the high points (Fig 1g). Short term follow up was done for the case (1h, 1i).

## **CASE REPORT- 2 (Fig 2)**

### Chief complaint, clinical examination and diagnosis:

21 years old male patient reported with the chief complaint of decay in his right lower back tooth and wanted the filling of the same tooth. He complained of food lodgment in the same tooth but there was no pain with respect to the same tooth. On visual examination, mandibular right first molar showed Class I extensive caries involving mesiobuccal and mesiolingual cusps, (Fig 2a). Probing test showed a negative result. There was no periodontal attachment loss on any surface. The periapical radiograph showed mesioocclusal radiolucency extending deep into dentin with no evidence of pulpal involvement (Fig 2b). The case was diagnosed

as occlusal cavitated carious disfigurement with deep dentin involvement.

### Treatment Procedure:

Soft caries excavation was done using a spoon excavator and arrested caries, after confirmation with caries detector dye (Caries Detector, Kuraray America, Inc.) was sealed with GIC. A thin layer of composite material (Filtek Z350, 3M ESPE; India) was bonded to the floor of the cavity. Two ribbon fibers (2mm width) (Ribbon bondable reinforcement ribbon, US) impregnated with bonding agent (Adper Single Bond, 3M ESPE; India), were bonded on the floor of the cavity in an L-shape manner, one fiber in buccolingual orientation and second in mesiodistal (Fig 2d). Further composite build up was done along the circumference of the involved lesion. Then a single ribbon fiber was bonded extending from distobuccal cusp following mesiobuccal axial line angle to mesiolingual axial line angle of the tooth till mesiolingual groove, sparing mesiolingual cusp (Fig 2e). Further cusps build up and occlusal adjustment was done (Fig 2f). Eleven months follow up was done (2g, 2h).

## **CASE REPORT- 3 (Fig 3)**

### Chief complaint, clinical examination and diagnosis:

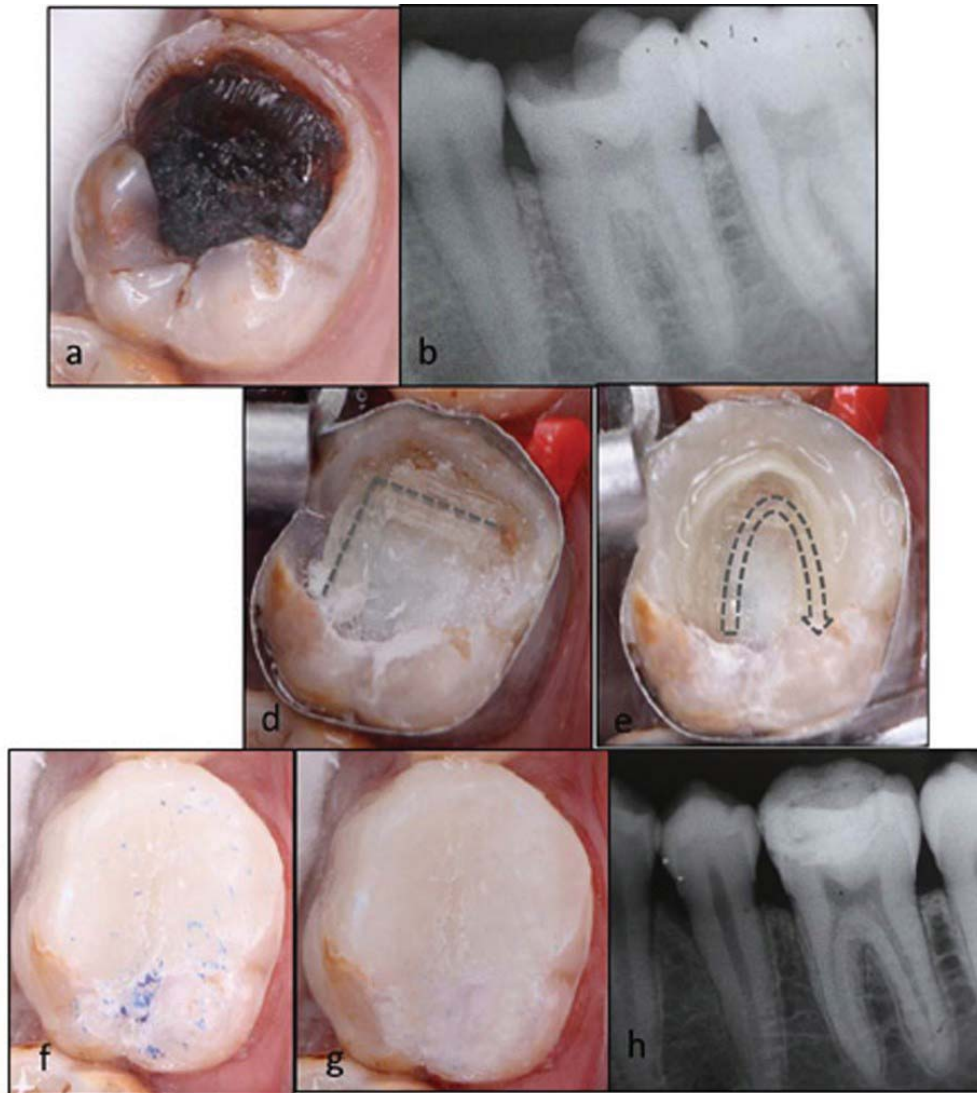
A 16 years old male patient reported with the chief complaint of hollowness in his right upper back tooth since 6 months. The case



was similar like Case1 with involvement of all four cusps and similar to case 2 with deep dentin involvement (Fig 3a). Periapical radiograph showed occlusal radiolucency extending in deep dentin without pulpal involvement. (Fig 3b)

#### Treatment Procedure:

The treatment protocol involved was the combination of treatments done in case 1 and case 2A thin layer of composite material (Filtek Z350, 3M ESPE; India) was bonded to the floor of the cavity after complete excavation of caries and pulp protection using GIC(Fig 3c). Two Ribbond fibers (Ribbond

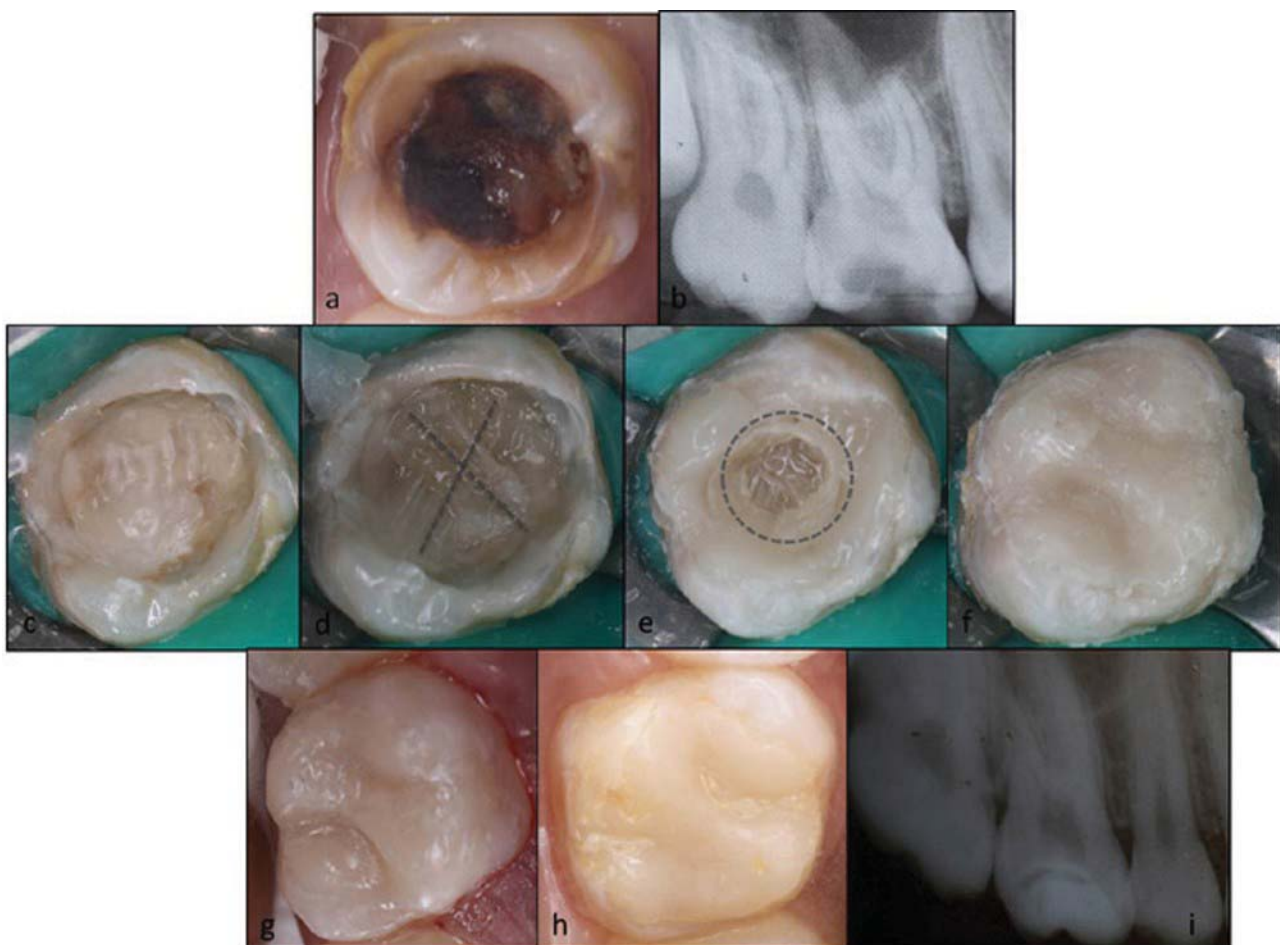


**Fig– 2: Case report 2**

- a.** Preoperative occlusal view of right mandibular first molar
- b.** Preoperative radiograph of right mandibular first molar
- c.** Pulp protection with glass ionomer cement
- d.** Two Ribbond fibers in L- shaped manner over the floor of composite restoration
- e.** Placement of fiber along the circumferential composite build up for the lost structure
- f.** Restoring cuspal anatomy with composite restoration
- g.** 11 months follow up
- h.** Post operative follow up radiograph

bondable reinforcement ribbon, US) of 2mm width of variable length, impregnated with bonding agent (Adper Single Bond, 3M ESPE; India) were placed obliquely on the floor of the cavity, one from mesiobuccal to distopalatal and another from distobuccal to mesiopalatal cusps, as shown in the fig (Fig 3d). Composite build up was done along the four cuspal inclines. Then a single ribbon fiber was bonded circumferentially along this

composite buildup.(Fig 3e) Further cusps build up was done using composite restoration (Fig 3f). Occlusal correction as well as finishing and polishing of the restoration were done (Fig 3g). A follow up of 10 months was done for the same (Fig 1h, 1i).



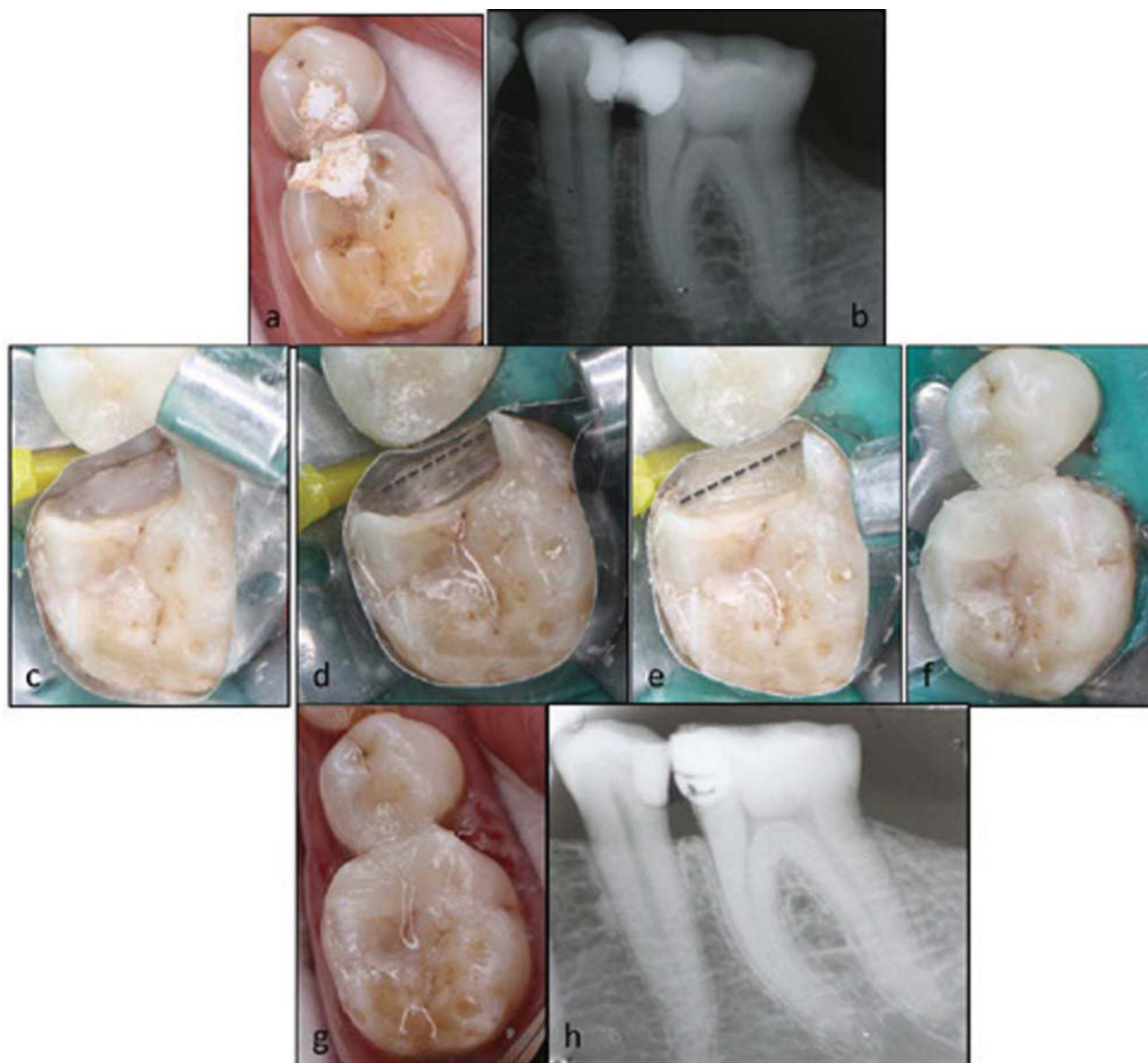Fig– 3: Case report 3

- a.** Preoperative occlusal view of right maxillary first molar
- b.** Preoperative radiograph of right maxillary first molar
- c.** Pulp protection with glass ionomer cement
- d.** Two Ribbon fibers placed obliquely over the floor of composite restoration
- e.** Circumferential placement of Ribbon along the cuspal inclines
- f.** Restoring cuspal anatomy with composite restoration
- g.** Immediate post operative occlusal view
- h.** 10 months follow up
- i.** Post operative follow up radiograph

**CASE REPORT- 4** (Fig 4)Chief complaint, clinical examination and diagnosis:

A 32 years old female patient reported with a chief complaint of fractured filling in her tooth. On visual examination, left lower back

teeth were filled with white colored temporary restoration (Fig 4a) Teeth were non tender on percussion with sound periodontal health. On removal of temporary restoration (Fig 4b), there was class II mesiobuccal caries in left lower first molar involving mesiolingual axial



**Fig– 4: Case report 4**

- a.** Preoperative occlusal view of left mandibular first molar
- b.** Preoperative radiograph of left mandibular first molar
- c.** First 1mm increment of composite material over the gingival seat
- d.** First Ribbond fiber in buccolingual direction over the gingival seat
- e.** Second Ribbond fiber in buccolingual direction over the gingival seat after second increment of composite material
- f.** Restoration using composite material
- g.** Post operative occlusal view
- h.** Post operative radiograph

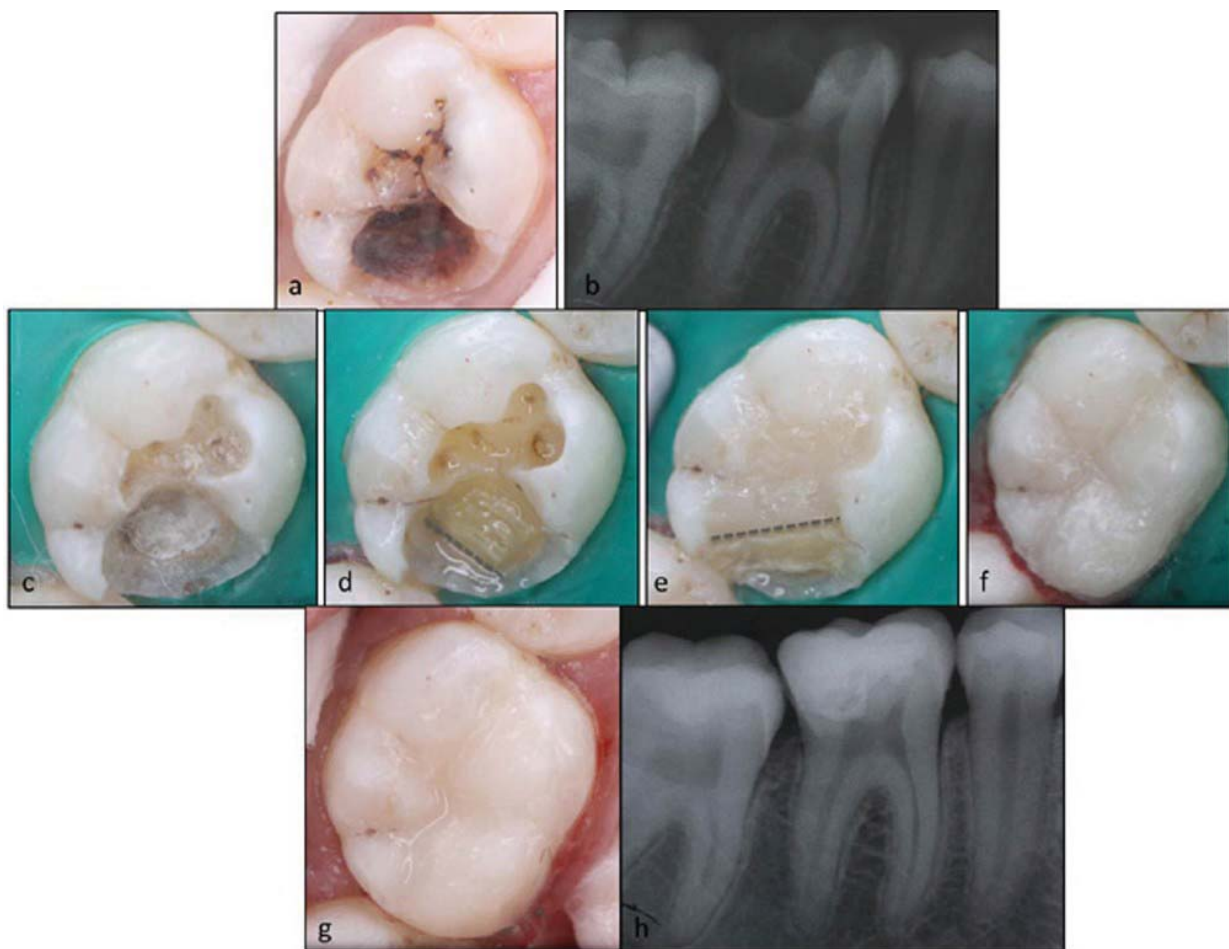


line angle of the tooth and Class II distobuccal caries in left second premolar involving the contact area.

#### Treatment Procedure:

After soft caries excavation, pulp protection was done using GIC on the axial walls of both the teeth. Premolar tooth was restored with composite. Depth of the axial wall of molar was around 5mm as estimated using a

calibrated periodontal probe. Approximately 1 mm increment of composite (Filtek Z350, 3M ESPE; India) was done on the gingival seat (Fig 4c), then a ribbon (Ribbond bondable reinforcement ribbon, US) of 2mm width impregnated with bonding agent (Adper Single Bond, 3M ESPE; India), was bonded from buccal to lingual side on the floor (Fig 4d). Second increment of composite was placed over ribbon and light cured. Second fiber



Fig– 5: Case report 5

- a.** Preoperative occlusal view of right mandibular first molar
- b.** Preoperative radiograph of right mandibular first molar
- c.** Pulp protection using glass ionomer restoration
- d.** First Ribbond fiber in buccolingual direction over the gingival seat
- e.** Second fiber in buccolingual direction over second composite increment at 45 degree incline extending from buccal proximal wall to the lingual proximal wall, covering the axial wall
- f.** Restoration using composite material
- g.** Post operative occlusal view

piece of 2mm width ribbon impregnated with bonding agent was placed (Fig 4e) and the cavity was restored with composite (Fig 4f). Occlusal rehabilitation, finishing and polishing was done (Fig 4g) and a radiograph was taken (Fig 4h).

### **CASE REPORT- 5** (Fig 5)

#### **Chief complaint, clinical examination and diagnosis:**

A female patient aged 22 years reported with a chief complaint of decay in her lower right back tooth without any pain. On visual examination, right mandibular first molar had class II caries involving distolingual cusp, extending beyond the lingual developmental groove (Fig 5a). Radiographically, disto-occlusal radiolucency very close to pulp chamber space was observed (Fig 5b). The case was diagnosed as reversible pulpitis.

#### **Treatment Procedure:**

Active carious lesion was excavated using a bur and spoon excavator. There was no exposure of pulp on thorough evaluation. Pulp protection was done using GIC (Fig 5c). First increment of composite (Filtek Z350, 3M ESPE; India) was placed over GIC in thin layer corresponding to the lingual developmental groove. The height of composite increment was limited to the inner third of dentin. Composite increment was light cured and ribbon fiber (Ribbon bondable reinforcement ribbon, US) of 2mm width impregnated with bonding agent (Adper

Single Bond, 3M ESPE; India) was placed over the composite increment (Fig 5d). Second increment of composite was layered over ribbon. The composite was extended from buccal proximal wall to the lingual proximal wall, covering the axial wall. Composite build up was done at 45 degree incline which covered most the cavity preparation leaving 1mm cavity from the cavosurface margin. Following light curing, second piece of ribbon of 2mm width, impregnated with bonding agent, extending from the buccal to lingual proximal wall was placed (Fig 5e). The remaining cavity was filled with last increment of composite and light cured (Fig 5f). Finishing and polishing of the restoration was done and a post operative radiograph was taken.(Fig 5g).

### **CASE REPORT- 6** (Fig 6)

#### **Chief complaint, clinical examination and diagnosis:**

A male patient reported with the complaint of decay in his lower right back tooth. Left mandibular first molar had Class I caries extending along the buccal developmental groove with partial loss of mesiobuccal and distobuccal cusps. (Fig 6a). The periapical radiograph showed occlusal radiolucency in inner third of dentin (Fig 6b).

#### **Treatment Procedure:**

Active carious lesion was excavated using a bur and spoon excavator. The cavity was protected with glass ionomer cement. Composite (Filtek Z350, 3M ESPE) build up



was done on mesiobuccal and distobuccal wall to create incline plane (Fig 6c). On each incline, 2mm width of ribbon fibers (Ribbond bondable reinforcement ribbon, US) impregnated with bonding agent (Adper Single Bond, 3M ESPE) were placed extending from the floor of the cavity to the 1.5 mm below the cavosurface margin (Fig

6d). Remaining cavity was restored with composite restoration. Finishing and polishing was done (Fig 6e). A short term follow up of around 8 months was done (Fig 6f, 6g) which revealed sound restoration other than little surface discoloration.

A brief description of all the cases has been given in Table 1.

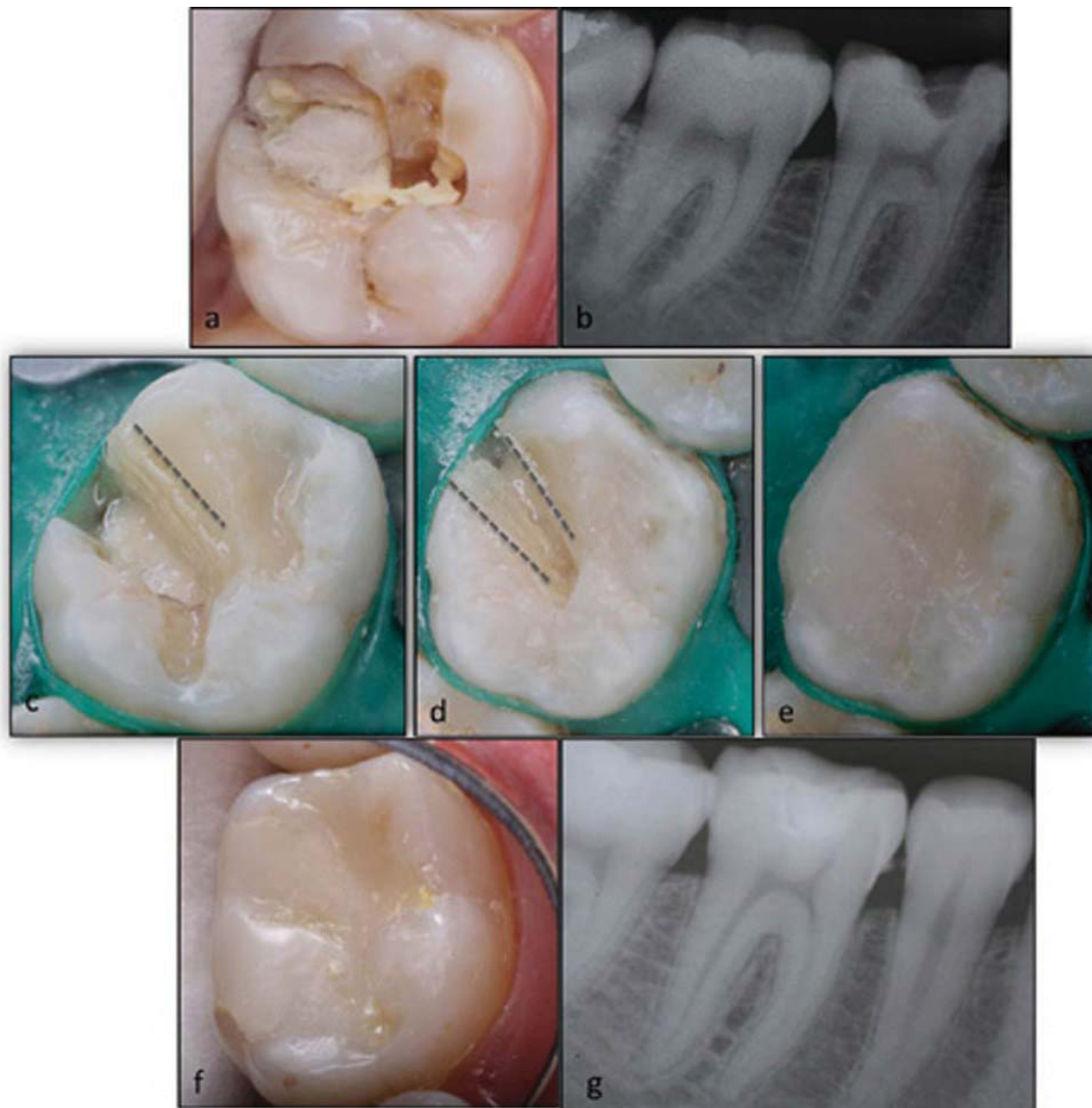

Fig- 6: Case report 6

- a.** Preoperative occlusal view of left mandibular first molar
- b.** Preoperative radiograph of left mandibular first molar
- c.** First fiber along the cuspal incline build up with composite for the lost mesiobuccal cusp
- d.** Second fiber along the cuspal incline build up with composite for the lost distobuccal cusp
- e.** Final restoration using composite material
- f.** Post operative occlusal view of 8 months follow up
- g.** Post operative follow up radiograph

Case Number	Tooth Number	Involvement	Reinforcement Required for	No of fibers	Direction of fibers	Rationale of Use
1	36	Class I caries in dentin with loss of four cusps	All four cusps	4	Oblique	Unilayered, discontinuous reinforcement in different directions for each lost cusp
2	46	Class I caries in deep dentin, loss of 2 cusps and 1 marginal ridge	2 cusps, 1 marginal ridge	3	2- Horizontal, 1 circumferential	Horizontal fibers for bilayer reinforcement, Circumferential for continuous reinforcement along the lost cusp and 1 marginal ridge in cavity depth of around 5 mm.
3	16	Class I caries with loss of 4 cusps & oblique ridge	4 cusps, oblique ridge	3	2 horizontal, 1 circumferential	Bilayered reinforcement for a cavity depth of around 4 mm, Circumferential for continuous reinforcement for lost oblique ridge.
4	36	Class II caries with wide contact and loss of lingual axial line angle	Axial line angle, Proximal box	2	2 horizontal	Bilayered, discontinuous reinforcement for a wide proximal box cavity ( 1 fiber in tension zone and other in compression zone)
5	46	Class II caries with loss of distolingual cusp	Distolingual cusp, proximal box	2	1horizontal, 1 oblique	Bilayered reinforcement, 1 fiber in tension zone and 1 oblique for the lost cusp
6	36	Class I caries with wide buccal extension	Loss of buccal cusp adjacent to developmental groove	2	Oblique	1 fiber for each lost cusp

Table 1- Description of treatment procedure for the case series

## **DISCUSSION**

Fiber reinforced composites can be used in dentistry for imparting flexural strength, fracture resistance, fatigue strength and increasing the tensile strength. The surface configuration of each filament has intrinsic mechanical roughness which helps to lock the filaments into composite mass. Here, all the cases were done with Ribbond which is a polyethylene fiber with patented leno weave pattern and lock stitch structure. There are some specific rules for doing complex amalgam, cast restorations and other complex restorations but as such no specific guidelines have been found in literature for using fibers in restorative dentistry till now. All the cases done above had specific rationale regarding the use of fibers. All the cases were done following the guidelines as are followed in Department of Conservative Dentistry and Endodontics, Bapuji Dental College and Hospital, Davangere, India. These guidelines have been proposed and published by Dr. Sathyanarayanan R.<sup>11</sup>

Table 2 gives the details of all the factors for the selection of fibers along with the advantages and disadvantages of each.<sup>7, 10, 11, 12, 13</sup>

After going through the previous literature search certain specific protocols were followed for doing all the cases<sup>10, 12, 13, 14, 15, 16, 17, 18</sup>. The description for them has been clearly mentioned in Table 1.

Two types of reinforcement can be considered, continuous and discontinuous.

Continuous reinforcement can be done using flexible fibers such as polyethylene fibers like Ribbond. Glass fibers have better mechanical properties and can be use for discontinuous reinforcement. Another factor to decide for placement of fibers is unilayer or bilayer reinforcement. In a tooth, the three zones for forces should always be considered before doing any restoration. Tension zone is considered near to the cervical region, compression zone around 1.5 to 2 mm below the occlusal surface and a neutral zone in between these two. There is still a controversy whether tension zone reinforcement or compression zone reinforcement provides better resistance to fracture. Previous studies have proved that placement of fibers at tensile side of composite resin specimens improves flexure properties<sup>10, 19, 20</sup> but the recent studies support compression zone as fracture resistance increases when fibers are placed close to the point where force is exerted because it leads to a shorter working arm according to lever principle.<sup>21</sup> Hence a bilayered reinforcement where placement is done in both the tension and compression zones, was decided for most of the cases, when the depth of the cavity is 4mm or more.

## **CONCLUSION**

Due to increasing concern for esthetics, the popularity of resin composites has shown a drastic increase during recent years. They still show problems related to technique sensitivity and polymerization shrinkage. The

FACTORS TO BE CONSIDERED	VARIOUS TYPES		CRITICAL ANALYSIS & GUIDELINES
Type of fiber	Glass fibers like (Splint-it: Jeneric-pentron co./Interlig: angelus co./Vectris: ivoclar co.)		Better mechanical properties Difficult to operate and adapt, can be used for direct chairside procedures Can provide small discontinuous reinforcement
	Polyethylene like (Ribbond inc. bondable reinforcement ribbon: Ribbond Co., US)		Mechanical properties inferior to glass fibers Can be manipulated easily and is effective for chairside procedures Can be used for both continuous and discontinuous reinforcement
Fiber architecture	Unidirectional		Not suitable as forces are from different directions
	Braided		Can resist multidirectional forces
	Woven		Can bear multidirectional forces and easy to manipulate
Resin impregnation	Done by using unfilled resins, bonding agents		Best done during chairside than preimpregnated fibers.
Layer of reinforcement	Acc to Zones	Tension Zone	Area near gingival third
		Neutral Zone	In between tension and compression zone
		Compression Zone	Area near occlusal third
	No of Layers	Unilayered	One layer of reinforcement for cavity depth within 3mm
		Bilayered	Two layers of fibers for 4-5 mm cavity depth
Width of fiber	2mm		For most of the restorative work
	3mm		For post endodontic restorations For circumferential reinforcement of pulp chamber
	4mm		For post endodontic restorations For very deep cavities
Direction of Reinforcement	Horizontal	Mesiodistally	For bilayered reinforcement Discontinuous reinforcement Wide proximal cavities For lost oblique ridge
		Buccolingually	
	Oblique	Cervico-occlusally	Reinforcing lost cusps Reinforcing wide proximal box with loss of axial angle Reinforcing wide buccal or palatal extension in Class I cavities
	Circumferential	Cervico-occlusally	For pulpal reinforcement Less often for lost cusps and marginal ridges

Table 2- Factors to be considered for fiber reinforcement (7, 10, 11, 12, 13, 14, 15)

performance of posterior resin composite restorations has reported failures due to material fracture, secondary caries, lack of interfacial adaptation and appropriate proximal contact.<sup>16, 17, 18</sup> Fiber-reinforcement can be a good option to increase the fracture resistance of materials. Restorative systems are mostly tested in vitro, but its value is often limited and clinical studies are required to test these materials in the oral cavity. The widespread applications of fiber reinforced

composites have been well established and discussed in literature. Searching through various evidence based literature, the guidelines have been framed highlighting the orientation and placement of fibers while doing fiber reinforced composite restorations.

## REFERENCES:

1. Baum L, Phillips RW, Lund MR. Classification of cavities and restorations. In: Operative Dentistry. 2nd ed. Philadelphia: WB Saunders Company; 1985.p.14-29.
2. Marzouk MA, Simonton AL, Gross RD. Pin and post retained non cast restorations and foundations. In: Operative Dentistry – Modern Theory and Practice. St. Louis; Ishiyaku EuroAmerica Inc: 2001.p.205-36.
3. Roberson TM, Sturdevant CM. Introduction to Amalgam Restorations. In: Roberson TM, Heymann HO, Swift EJ. Sturdevant's Art & Science of Operative Dentistry. 4th ed. St. Louis: Elsevier Publishers; 2004.p. 271-305.
4. Turkun LS, Aktener BO. Twenty-four-month clinical evaluation of different posterior composite resin materials. J Am Dent Assoc 2001; 132: 196-203.
5. Gouroshi SK, Lassila LVJ, Vallitu PK. Fiber reinforced composite substructure: Load bearing capacity of an onlay restoration. Acta Odontol Scand 2006; 64: 281-5.
6. Karbhari VM, Wang Q. Influence of triaxial braid denier on ribbon based fiber reinforced dental composites. Dent Mat 2007; 23: 969-976.
7. Premnath k, Sharmila MR, Kalavathy N. Bonding with ribbon-single visit fixed partial denture. SRM Univ Dent Sc 2010; 1(1): 134-6.
8. Freilich MA, Meirs JC, Duncan JP, Goldberg AJ. Composition, architecture and mechanical properties of fiber – reinforced composites. In: Fiber-reinforced composites in clinical practice. Chicago: Quintessence Publishing Co inc.; 2000. pp 49-70.
9. Van Dijken JWV, Grönberg KS. Fiber-reinforced packable resin composites in Class II cavities. J Dent 2006; 34: 763-769.
10. Dyer SR, Lassila LVJ, Jokinen M, Vallittu PK. Effect of fiber position and orientation of fracture load of fiber reinforce composite. Dent Mat 2004; 20: 947-955.
11. Carounanidy U, Sathyanarayanan R. Guidelines for fiber reinforced composite restorations. Restorative and Endo Data online. India: REDO, 2012. Available from [http://www.onlinedentallearning.com/index.php?option=com\\_content&task=view&id=677&Itemid=487](http://www.onlinedentallearning.com/index.php?option=com_content&task=view&id=677&Itemid=487) (accessed 6 April 2012)
12. Belli S, Erdemir A, Ozcopur M, Eskitascioglu G. The effect of fiber insertion on fracture resistance of root filled molar teeth with MOD preparations restored with composite. Int Endod J 2005; 38: 73-80.
13. Belli S, Eskitascioglu G. Biomechanical properties and clinical use of a polyethylene fibre post-core material. International Dentistry South Africa 2006; 8: 20-26.
14. Rashidan N, Esmaceli V, Alikhasi M, Yasini S. Model system for measuring the effects of position and curvature of fiber reinforcement within a dental composite. J Prosthodont 2010; 19(4): 274-8.
15. Maghrabi AA, Ayad MF, Godoy FG. Relationship of margin design for fiber reinforced composite crowns to compressive fracture resistance. J Prosthodont 2011; 20 (5): 355-60.
16. Manhart J, Kunzelmann KH, Chen HY, Hickel R. Mechanical properties and wear behavior of light-



- cured packable composite resins. Dent Mater 2000; 16: 33-40.
17. Kim KH, Ong JL, Okuno O. The effect of filler loading and morphology on the mechanical properties of contemporary composites. J Prosthet Dent 2002; 87: 642-649.
  18. Pilliar RM, Smith DC, Maric B. Fracture toughness of Dental Composites determined using the short-rod fracture toughness test. J Dent Res 1986; 65: 1308-14.
  19. Ellakwa AE, Shortall AC, Shehata MK, et al. The influence of fiber placement and position on the efficiency of reinforcement of fibre reinforced composite bridge work. J Oral Rehabil 2001; 28: 785-91.
  20. Hamza Ta, Rosensteel SF, Elhosary MM, et al. The effect of fiber reinforcement on the fracture toughness and flexural strength of provisional restorative resins. J Prosthet Dent 2004; 91: 258-64.
  21. Oskoe A, Ajaml AA, Navimipour J. Effect of three composite fiber insertion techniques on fracture resistance of root filled teeth. JOE 2009; 35: 413-6.

**Address for correspondence:**

Dr. Barkha J  
House No. MIG-64,  
New Avas Vikas Colony,  
Hari Mandir Road,  
Saharanpur, Uttar Pradesh  
247001. India.  
barkha1511@gmail.com

**Authors:**

<sup>1</sup> Dental Consultant,  
Centre Hospitalle Regional de Mouila,  
B.P. 37, Mouila,  
Gabon.

<sup>2</sup> Professor,  
Department of Conservative Dentistry and Endodontics,  
Indira Gandhi Institute of Dental Sciences,  
Sri Balaji Vidyapeeth University  
Puducherry

**How to cite this article:**

Barkha J, Sathyanarayanan R. A Conservative Approach for Restoration of Grossly Decayed Vital Posterior Teeth using Fiber Reinforced Composites-A Case Series. Journal of Scientific Dentistry 2014;4(1):9-23

**Source of Support:** Nil, **Conflict of Interest:** None declared