

CASE REPORT

Evaluation of Speech for a Patient with an Extensive Soft Palate Defect, Before and After Fabrication of Obturator

Cholan R¹, DilipKumarM², Vidyashree NV³

ABSTRACT

Maxillary obturator prostheses restore the congenital or acquired defects of the soft palate and allow adequate closure of palatopharyngeal sphincter. Our patient, a 30-year-old female with a diagnosis of soft palate defect presented with complaints of speech difficulty and hyper-nasality. There was history of surgery for ameloblastoma of hard and soft palate one month ago. Intra oral examination revealed a soft palate defect. Since the patient had full dentition, pharyngeal obturator with clasp retention was given. Adequate velopharyngeal closure was detected after the patient was examined during drinking water in the upward head position. Moreover no nasal reflux was observed. A speech pathologist confirmed that the hyper-nasality was reduced immediately and advised for speech training classes. The production of oral and nasal consonants and the speech was noticeably improved after perceptual speech evaluation. We therefore emphasize the integration of an interdisciplinary team in order to increase the efficacy of rehabilitation and the quality of life of these patients.

Keywords: Pharyngeal Obturator, Velopharyngeal insufficiency, Hyper-nasality, Speech intelligibility

The maxillofacial prosthodontist often receives referred patients who undergo partial surgical resection of the maxilla (Maxillectomy) as a part of cancer therapy. One of the main impacts of patients submitted to maxillectomy is the impairment of speech intelligibility. The undesirable coupling between the oral and nasal cavities reduces intraoral air-pressure during speech production causing articulatory imprecision, hyper-nasal speech, nasal air emission, and reduced vocal loudness, which interferes with the quality of life⁽¹⁾.

The defects created by maxillectomy can be repaired by prosthetic obturation or surgical reconstruction. However an obturator is still considered to be one of the best rehabilitation

tools in maxillary resections due to its rapid accomplishment, low cost, and the possibility of modification according to the patient needs. The aim of the obturator prosthesis is to obliterate the undesired communication between the oral and nasal cavities created by the tumor resection surgery, and to improve speech intelligibility and swallowing.

The soft palate acts as a dynamic separator between oral and nasal cavity⁽²⁾. The soft palate,

Scan the QR code with any smart phone scanner or PC scanner software to download/ share this publication



lateral and posterior pharyngeal walls form the velopharyngeal closure so that all of them create a three dimensional muscular valve which is known as velopharyngeal sphincter. The velopharyngeal closure pattern depends on the contraction degree of the sphincter components⁽³⁾. Adequate velopharyngeal closure is required during swallowing and production of all consonants except for the nasal ones⁽⁴⁾. Impairment of velopharyngeal function can be due to insufficiency or incompetency^(5,6). Velopharyngeal insufficiency is distinguished by speech and nasal resonance abnormalities related to defects of the soft palate, which may be congenital as in cleft lip and palate or acquired as in palatal tumor resection⁽⁷⁾. Velopharyngeal incompetence describes dysfunction of an anatomically intact velopharyngeal mechanism as in patients with neuromuscular disorders^(4,5).

The primary effects of the velopharyngeal insufficiency are airflow escape and hypernasality^(8,9). Secondary effects are disorders in speech articulation (distortions, substitution and omissions)^(6,8). Velopharyngeal insufficiency causes communication problems because of distortion in speech, resonance and articulation apart from swallowing disturbances^(8,9,10). Mahidet al⁽¹¹⁾ reported on speech intelligibility of post-surgical maxillectomy patients with and without a prosthesis in the mouth. Their study showed better speech intelligibility with prosthetic obturation.

This clinical report is about the evaluation the speech of a patient with an extensive soft palate defect, before and after fabrication of obturator.

CASE REPORT

A 30 year old female with velopharyngeal insufficiency was referred to the department of

prosthodontics with diagnosis of soft palate defect. She had speech difficulty, hyper nasality in speech and hence a communication problem. Her medical history revealed that she underwent surgery for ameloblastoma of hard and soft palate one month prior to the referral. Intra oral examination revealed soft palate defect (Fig.1). She was talking with soft intensity to decrease the nasal emissions. Speech difficulty and hyper nasality were also detected in clinical examination. Speech evaluation was performed by a speech pathologist. The speech evaluation consisted of assessing resonance, the occurrence of inappropriate nasal air emission and articulation

The patient refused to have a surgical reconstruction done and hence a prosthetic restoration was planned. A pharyngeal obturator with clasp retention was planned since the patient had full dentition. Preliminary impression is made with irreversible hydrocolloid (Chromatic Jeltrate, DENTSPLY, India) to fabricate custom tray with a pharyngeal bulb or extension (Fig.2). Secondary impression of pharyngeal bulb was made with modeling plastic impression compound (DPI PINACLE, India) during the functional movements of the patient. The patient was asked to move her head in a circular manner from side to side, to extend her head as far forward and backward as possible and to say 'ah' and swallow. Afterwards final impression was made with light-body elastomeric impression material (Aquasil LV Addition Reaction silicone, DENTSPLY, USA) (Fig.3) and whole custom tray picked up with irreversible hydrocolloid (Chromatic Jeltrate, DENTSPLY, India) (Fig.4). The pharyngeal obturator with bulb was fabricated according to the impression using chemically cured acrylic resin (DPI-RR Cold Cure, Denture Base Polymer

resins, India). The obturator was processed using a pressure pot and prosthesis was delivered to the patient after necessary adjustments and relining with auto-polymerising soft liners (GC Soft liner, Japan) (Fig.5).

Adequate velopharyngeal closure was

detected after the patient was examined during drinking water in the upward head position. Moreover no nasal reflux was observed. . The patient was asked to count from 1 to 20 and to repeat 20 words which included all phonemes of the tamil language⁽¹²⁾ and hypernasality was

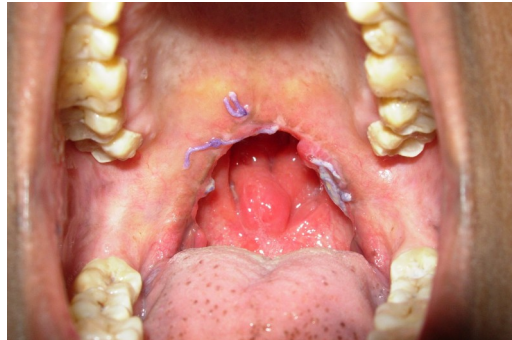


Fig 1: Intraoral view of the patient with soft palate defect

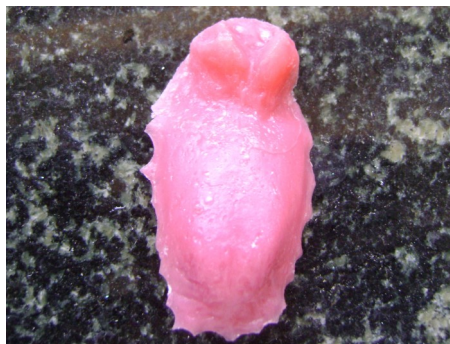

Fig 2: Custom tray with Pharyngeal bulb

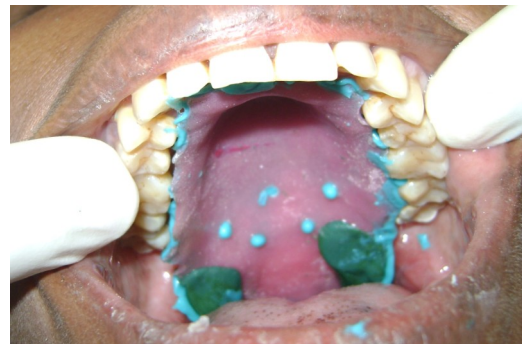

Fig 3: Final impression



Fig 4: Pick up impression

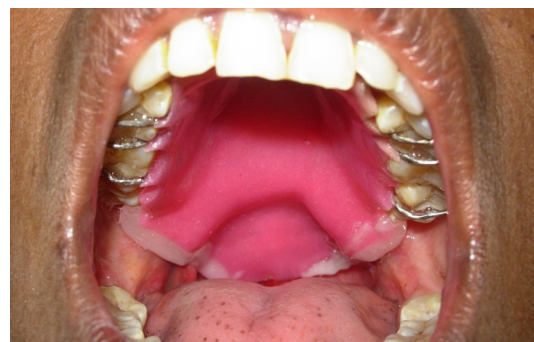

Fig 4: Intra oral view of the final denture with soft liner

0	Absent
1	Mild – Evident but acceptable
2	Mild/ Moderate – Unacceptable distortion evident on high vowels
3	Moderate – Evident on low and high vowels
4	Moderate/ Severe – Evident on all vowels and consonants
5	Severe, evident on all vowels and most voiced consonants

Table 1: Scale for evaluation of hypernasality¹³

evaluated using a scale of 5 by a speech pathologist⁽¹³⁾. Speech pathologist confirmed that the hyper-nasality was reduced immediately and advised for speech training classes. The production of oral and nasal consonants and the speech was noticeably improved after perceptual speech evaluation. The patient was trained in oral hygiene and instructed in the specific care for her new prosthesis. The checkups were done at 1st week, 2nd week, 1 month and 6 months after insertion of the prosthesis and relining was done subsequently, whenever required.

DISCUSSION

The objectives of obturation are to provide the capability for control of nasal emission and inappropriate nasal resonance during speech and to prevent the leakage of material into the nasal passage during deglutition^(7,8,9). To achieve normal speech with a prosthesis, an accurate prognosis is extremely important for the patients exhibiting considerable movement of the residual velopharyngeal complex during function^(1,9). Because the movement of the lateral pharyngeal walls is essential for the control of nasal emission, little or no movement of Velopharyngeal mechanism makes it difficult to achieve normal speech with either surgical reconstruction or prosthetic therapy^(3,4,5,9,14).

In the literature, several types of prosthesis have been described to improve speech ability^(5,7,9,15,16,17). A Pharyngeal obturator prosthesis may prevent the hyper nasality and /or nasal emission associated with velopharyngeal inadequacies^(5,7). In order to obtain adequate Velopharyngeal closure during speech and swallowing, a posterior extension is added to prosthesis^(7,18). The extension should be positioned at the level of hard palate during the most active

movement of pharyngeal sphincter^(8,14). This movement can be achieved by asking the patient to say 'ah' or by touching to posterior wall of the pharynx with an instrument to initiate gag reflex^(8,18). An acrylic resin must be formed functionally. This extension must be in static contact with the soft tissues and must not affect the stability of the prosthesis^(2,8). The impression should be examined for contact with the pharynx bilaterally and posteriorly⁽¹⁸⁾. In the present case, patient was allowed to drink water to test the complete closure of the anatomical defect of soft and hard palate. The water should not reflux into the nasal cavity when the patient is in upright position.

The success of the prosthesis to obturate a soft palate defect depends on the functional adaptation of the impression material⁽¹⁹⁾. In the current case, modeling plastic impression compound was used in functional contouring of the palatal defect and velopharyngeal portion. Elastomeric polyvinylsiloxane impression material was added to make the final impression⁽²⁰⁾. Zinc oxide eugenol impression material was ruled out because it may cause irritation to soft tissues as the surgical site was a recent one.

Retention of pharyngeal obturator can be obtained by direct and indirect retainers for patients with complete maxillary dentition. In this case simple circular clasp and ball end clasp was given for additional retention. The weight and length of the obturator portion increases the effect of gravitational forces and the potential for rotation around fulcrum line. The effect of extension will be most significant for patients requiring a Kennedy Class I or Class II removable partial denture and minimal for patients with Class III or Class IV removable partial dentures⁽⁸⁾. For patients requiring Class I or class II partial

dentures, multiple indirect retainers are suggested, which will tend to resist the downward displacement of the obturator and increase the stability of the prosthesis⁽²¹⁾.

The degree of the defect affects the functions of the obturator. If the defect includes both soft and hard palate resections, the discomfort in the usage of obturator increases⁽²²⁾. Most individuals with a history of radiation therapy have poor satisfaction with obturator function due to their dry mouth⁽²²⁾.

The treatment of velopharyngeal insufficiency requires multidisciplinary approach. Accordingly, a speech pathologist should participate in treatment of these cases to test articulation errors and inappropriate oro-nasal resonance balance⁽¹⁹⁾. Perceptual and instrumental measures of hyper-nasality and nasal escape along with profile of patient's articulation provide the diagnostician information about the frequency and consistency of Velopharyngeal insufficiency. These measures, however, provide only limited information about the functioning of the Velopharyngeal mechanism. The use of MultiView Fluoroscopy and/or Nasal Endoscopy may contribute to the diagnostic confirmation of the assessment of velar mobility, pattern of velar elevation, size of residual Velopharyngeal gap and

lateral pharyngeal wall displacement while the patient is producing a standardized sample of connected speech. It may also contribute the assessment of the treated patients with Velopharyngeal insufficiency^(23,24).

In present case, no nasopharyngoscopic evaluation was made. However, perceptual speech evaluations demonstrated significant improvements in speech ability and Velopharyngeal function. The patient was asked to count from 1 to 20 and to repeat 20 words which included all phonemes of the tamil language⁽¹²⁾. Speech resonance was judged by the speech pathologist using a 5-point scale, in which 1 represented mild – evident hypernasality but acceptable and 5 represented very severe hypernasality, evident on all vowels and most voiced consonants⁽¹³⁾. The patient here showed a scale of 4 after wearing the obturator.

CONCLUSION

In this clinical report, patient with extensive soft palate defect who had velopharyngeal insufficiency was successfully treated by the obturator. We therefore emphasize the integration of an interdisciplinary team in order to increase the efficacy of rehabilitation and the quality of life of these patients.

REFERENCE:

1. Plank DM, Weinberg B, Chalian VA. Evaluation of speech following prosthetic obturation of surgically acquired maxillary defects. *J Prosthet Dent*. 1981;45(6):625-638.
2. Zarb GA, Blonder CL. Prosthodontic treatment for edentulous patient: complete dentures and implant-supported prosthesis. In: Jacob RF. *Maxillofacial prosthodontics for the edentulous patient*. St.Louis: Mosby; 2004. p. 449-470.
3. Skolinck L, McC all GN, Barnes M, the sphincteric mechanism of velopharyngeal closure. *Cleft palate JProsthet Dent* 1973;10:286-305.
4. Johns DF, Rohrich RJ, Awada M. Velopharyngeal incompetence: a guide for clinical evaluation. *PlastReconstrSurg J* 2003;112: 1890-1897.
5. Wolfaardt JF, Wilson FB, Rochet A, McPhee L. An appliance based approach to the management to the management of palatopharyngeal incompetency. A clinical pilot project. *J Prosthet Dent* 1993;69:186-195.
6. Ragab A.C erclage sphincter pharyngoplasty: A new technique for velopharyngeal insufficiency. *Int J PediatrOtorhinolryngoly* 2007;71:793-800.
7. Saunders TR, Oliver NA. A speech-aid prosthesis for

- anterior maxillary implant-supported prosthesis. J Prosthet Dent 1993;70:546-547.
8. Beumer III J, Curtis TA, Marunick MT. Maxillofacial rehabilitation: prosthodontic and surgical considerations: speech, velopharyngeal function, and restoration of soft palate defects. St Louis: IshiyakuEuroAmerica, Inc;1996.p.285-324.
 9. Yosida H, Michi K, Yamashita Y, Ohno K. A comparison of surgical and prosthetic treatment for speech disorders attributable to surgically acquired soft palate defects. J Oral Maxillofac Surg 1993;51:361-365.
 10. Werkmeister R, Szulczewski D, Walteros-Benz P, Joos UJ. Rehabilitation with dental implants of oral cancer patients. J Craniomaxillofac Surg 1999;27:38-41.
 11. Majid AA, Weinberg B, Chalian VA. Evaluation of speech following prosthetic obturation of surgically acquired maxillary defects. J Prosthet Dent 1974;32:87-88.
 12. Usha D. Test for articulation in tamil. Dissertation submitted to the University of Madras for completion of Master of Science; 1986.
 13. Sweeney T, Sell D. Relationship between perceptual ratings of nasality and nasometry in children/adolescents with cleft palate and/or velopharyngeal dysfunction. Int J Lang Comm Dis 2008;43(3):265-282.
 14. Tachimura T, Nohara K, Wada T. Effect of placement of a speech appliance on levator veli palatini muscle activity during speech. Cleft Palate Craniofac J 2000;37:478-482.
 15. De Carvalho WR, Barboza EP, Caula AL. Implant-retained removable prosthesis with ball attachments in partially edentulous maxilla. Implant Dent 2001;10:280-284.
 16. Tuna SH, Pekkan G, Buyukgural B. Rehabilitation of an edentulous cleft lip and palate patient with a soft palate defect using a bar retained, implant-supported speech aid prosthesis: a clinical report. Cleft Palate Craniofac J 2009;46:97-102
 17. Leonard TJ, Gillis R. Differential effects of speech prostheses in glossectomized patients. J Prosthet Dent 1990;64:701-708.
 18. Keyf F, Sahin N, Aslan Y. Alternative impression technique for a speech-aid prosthesis. Cleft Palate Craniofac J 2003;40:566-568.
 19. Abreu A, Levy D, Rodriguez E, Rivra I. Oral rehabilitation of patients with complete unilateral cleft lip and palate using an implant-retained speech aid prosthesis: clinical report. Cleft Palate Craniofac J 2007;44:673-677.
 20. Petrie CS, Walker MP, Williams K. A survey of US prosthodontists and dental schools on the current materials and methods for final impressions for complete denture prosthodontics. J Prosthodont 2005;14:253-262.
 21. Jacob RF, King G. Indirect retainers in soft palate obturator design. J Prosthet Dent 1990;63:311-315.
 22. Rieger JM, Wolfaardt JF, Jha N, Seikaly H. Maxillary obturators: the relationship between patient satisfaction and speech outcome. Head Neck 2003;25:895-903.
 23. Seagle MB, Mazaheri MK, Dixon-Wood VL, Williams WV. Evaluation and treatment of velopharyngeal insufficiency: the university of Florida experience. Ann Plast Surg 2002;48:464-470.
 24. Lam DJ, Starr JR, Perkins JA, Lewis CW, Eblen LE, Dunlap J, Sie KC. A comparison of nasendoscopy and multiview videofluoroscopy in assessing velopharyngeal insufficiency. Otolaryngol Head Neck Surg 2006; 134:394-402.

Address for correspondence:

Cholan R
 Department of Prosthodontics and Implantology
 SRM Kattankulathur Dental College and Hospital
 Kanchipuram District
 E mail:cholan.ramanujam@gmail.com

Authors:

¹Senior lecturer, ²Reader, ³Professor
 Department of Prosthodontics and Implantology
 SRM Kattankulathur Dental College and Hospital
 Kanchipuram District

How to cite this article:

Cholan R, Dilip Kumar M, Vidyashree NV. Evaluation of Speech for a Patient with an Extensive Soft Palate Defect, Before and After Fabrication of Obturator. Journal of Scientific Dentistry 2014;4(2):34-39

Source of Support: Nil, **Conflict of Interest:** None declared